

Pelvic Girdle

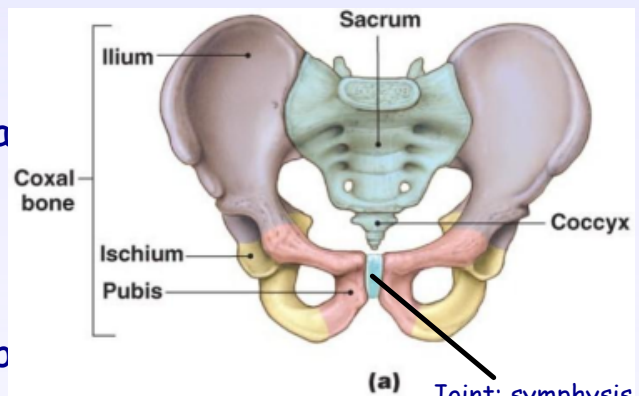
-2 coxae (hipbones)

Pelvis= sacrum, coccyx, and coxa

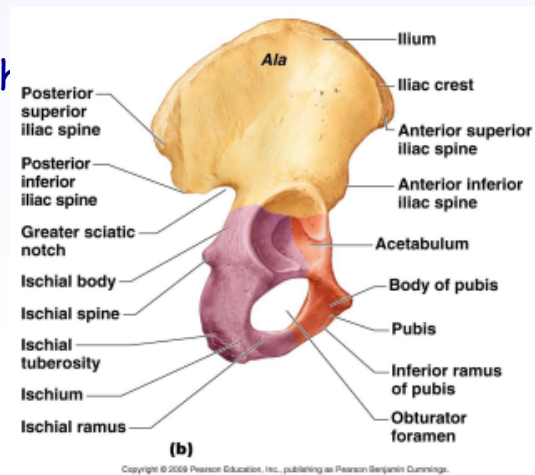
-Each coxa is made up of three p

1. Ischium
2. Ilium
3. Pubis

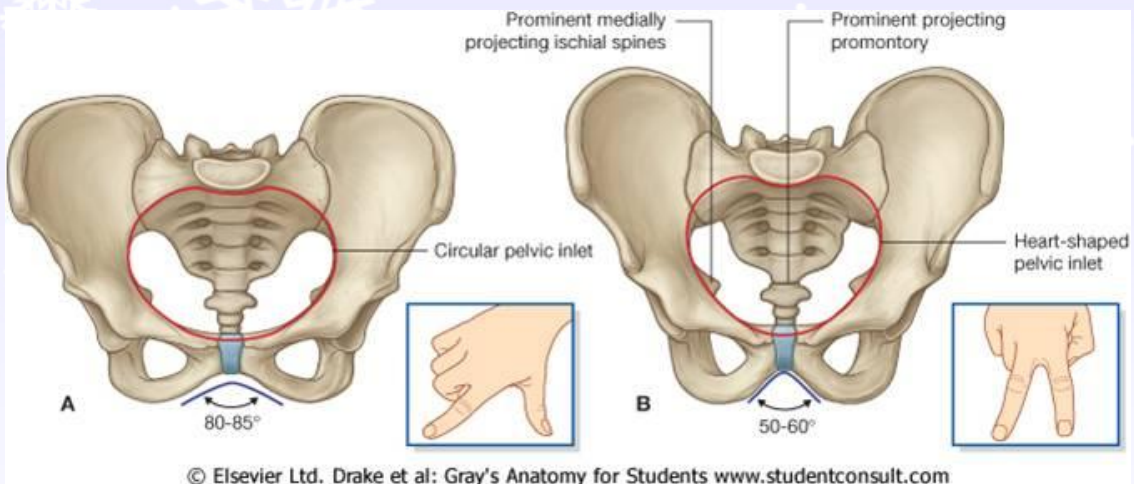
-Acetabulum- cup-shaped region w/



Joint: symphysis pubis



mur



© Elsevier Ltd. Drake et al: Gray's Anatomy for Students www.studentconsult.com

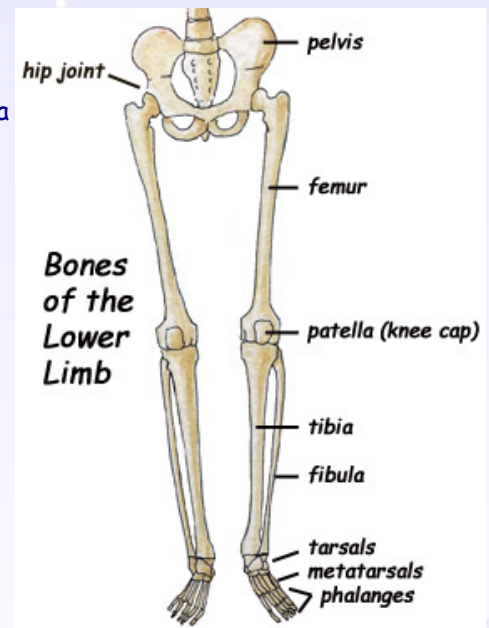
Lower Limb

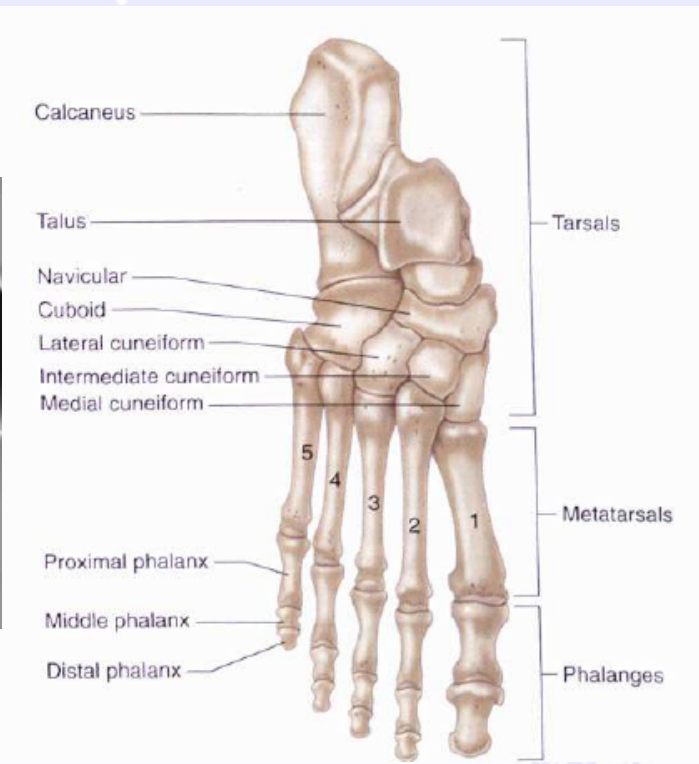
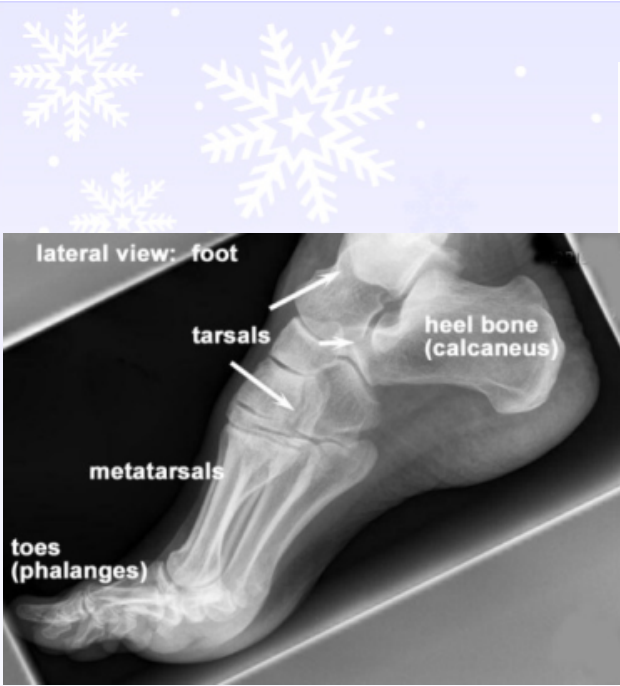-Thigh, leg, foot

-Femur, tibia, fibula, tarsals, metatarsals, phalanges, patella

*Patellar dislocation

*Fibula does not bear any body weight





*Flat feet